Lab 2

Skeletons and Locomotion

Objectives

The objectives of this and next week's labs are to introduce you to the comparative skeletal anatomy of vertebrates. As you examine the skeleton of each lineage, notice how the same components have been repeatedly modified for flight, walking, or swimming.

Introduction

Vertebrates possess tissues with varying degrees of mineralization. They produce a unique mineral called **hydroxyapatite** made of calcium and phosphorus. It is very hard and less resistant to dissolving in acidic solutions than calcium carbonate. The hardness of hydroxyapatite allows it to be easily fossilized, and in some cases, we only have fossils of teeth for some extinct organisms. The hydroxyapatite crystals are aligned on collagen providing the structure strength with relative lightness. There are six types of mineralized tissues in vertebrates, each tissue arises from a different cell type in development. For this lab we are most interested in the four listed below

Cartilage: Cartilage is formed by a specialized cell called chondrocytes. Cartilage is not typically mineralized, except in the gnathostomes or jawed vertebrates, including sharks. There is some evidence that sharks lost true bone. Cartilage does not have a direct blood supply, nor does it have nerve cells. Nutrients and gases must diffuse to cartilage.

Bone: Bone is made by specialized cells called osteocytes. Bone is different from cartilage and in the bony vertebrates (fish), bone can replace cartilage during development from juvenile to adult stages. Bone does have vascular tissue and nerve cells. Bones can also respond to the environment, if an organism experiences mechanical stress, bones can enlarge and become denser. If use decreases, then bones can atrophy in size and density. This is why weight lifting is a good way to prevent osteoporosis (the weakening of bones) later in life.

Enamel and dentine: Both of these mineralized tissues are used to form teeth. The enamel is on the outside and surrounds the dentine that houses the pulp inside the tooth. These mineralized tissues are very tough and are among the most common fossils found.

This focus of this lab is on comparing and contrasting the skeletons of the major vertebrate groups including the jawless fish, cartilaginous fish, bony fish, amphibians, turtles, lizards/snakes, birds, and mammals. As you view each group, notice how the vertebrate skeleton is continually modified for life in water, on land, or in flight. You can see how similar structures are repeatedly modified for the different lifestyles. Skulls are also a defining character of vertebrates, in fact, some people refer the vertebrata as the craniata. A major adaptation that was of immense importance for the success of vertebrates was the evolution of the jaws with teeth forming gnathostome lineage. Pay close attention to changes in the skull and teeth in each lineage because they are important for understanding what these organisms may have been feeding on.

In addition to the evolution of jaws and mineralized teeth, vertebrates also evolved paired appendages providing for much more maneuverability. In the tetrapods, the fins of lobed-fin fish became modified into limbs, originally allowing these animals to walk on land. In lepidosauria (lizards and snakes) and the caudates (salamanders), the limbs are similar to the ancestral condition, whereas in the synapsids (Mammals) the limbs are under the body providing them much more mobility. Flight evolved at least three times in the tetrapods; pterosaurs, birds, and the bats. As you examine the birds and bats, notice once again how the bones of the forelimbs are modified into wings. Because birds and bats independently evolved flight, there wings are different in the usage of the same bones.

As you work through each vertebrate group, keep in mind which features are plesiomorphic or synapomorphic. It may help to construct a phylogenetic tree that includes each of the groups in lab. There are many bones in each vertebrate group, and each bone has various parts which are also named as shown in Figure 2.1, which depicts a single human lumbar vertebrae.

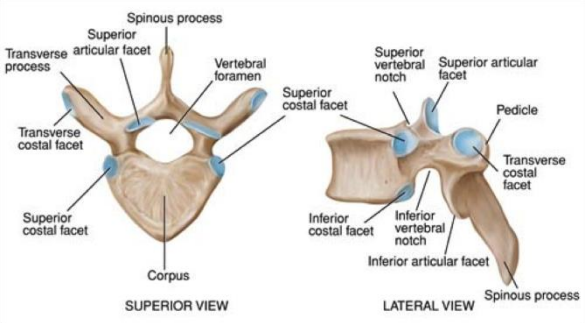

Figure 2.1 the front and side view of a vertebra to illustrate the various features of a single bone.

For this lab, we are going to focus on a few parts of the vertebrate skeleton to see how it has been modified in each group. Below are the major structures you should focus on

Cranial: Recall that some scientists refer to the vertebrata lineage as craniata, therefore you should closely examine the skull of each group. Pay close attention to the jaws that form the mouth and the teeth. In vertebrates, the lower jaw is actually the first pharyngeal arch that has been greatly modified. In the tetrapods the skull is repeatedly modified to match various lifestyles.

Teeth: true teeth, capped with enamel, are unique to the vertebrates. Teeth can aid in the capture of prey and are strong enough to crush the shells of their prey. Modern mammals are heterdont, meaning the teeth are different throughout the mouth, just think about canines and incisors. Mammals also possess only two sets of teeth, the milk (baby) teeth, which are lost and replaced by the adult teeth. Reptiles, amphibians and fish are homodont, meaning the teeth are relatively the same throughout the mouth. Homodonts also replace their teeth throughout their life.

Vertebral column: Having mineralized tissue surrounding the spinal cord is a defining feature of this lineage, in addition to the cranium. The purpose of the vertebral column is to protect the spinal cord. For vertebrates, the notochord becomes reduced as the vertebrae increase in prominence. In fish, the notochord is surrounded by the vertebral column. In tetrapods, the notochord is reduced to the gelatinous disk between the vertebrae. By forming the disc between vertebrae segments in the tetrapods, provides an extra cushion required because of gravity acting on the animal.

Living in water, fish don't require a cushion between their vertebrae. Secondly, the vertebrae differentiate, or change form, especially in the tetrapods. In fish, notice that the vertebral column begins with the cranium and ends in the tail with little change in each segment. In tetrapods, the vertebrate become modified to support limbs allowing them to walk in land. Pay attention to the main regions of tetrapod backbone **(cervical, thoracic**, **lumbar**, **Sacral**, and **caudal region**) and how they are modified in each lineage. Keep in mind that these regions can also be reduced or even lost in some groups.

The cervical vertebrae attach the cranium and allow it to move. The thoracic vertebrae are easily identified because the

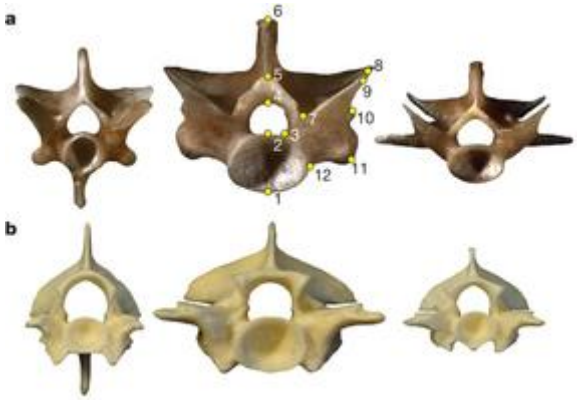

ribs attach to them. The lumbars are free floating between the thoracic vertebrae and the sacral vertebrae. The sacral vertebrae are fused and form part of the pelvic girdle.

Pectoral girdle and limbs: Tetrapod limbs evolved from lobed-fin fish fins. The pectoral girdle is a set of bones that connect the forelimbs to the skeleton. In Tetrapods, the number of bones ranges from three (clavicle, scapula, and coracoid), to two in humans (clavicle and scapula), to one in dogs (scapula). Tetrapod limbs, follow a pattern of one bone (humerus), two bones (radius and ulna) and lots of bones (carpals, metacarpals, phalanges)

Pelvic girdle and limbs: The pelvic girdle is a set of bones that connect the hind limbs to the skeleton. In the tetrapods, there is a lot of variation based on the life style of each

group. Basically, there are three main bones, the ilium, the ischium, and the pubis that form the pelvic girdle. These bones become fused or even greatly reduced in many species as they adapted to life on land. Fused bones can make the pelvic girdle stronger.

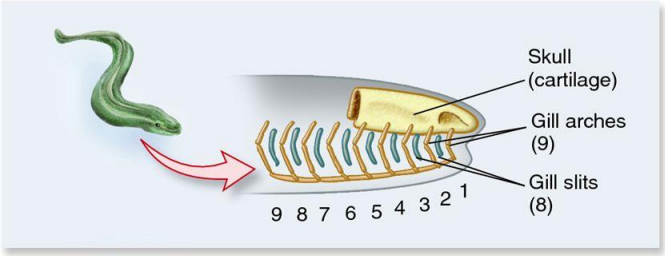

(a) Ancestral jawless fishes

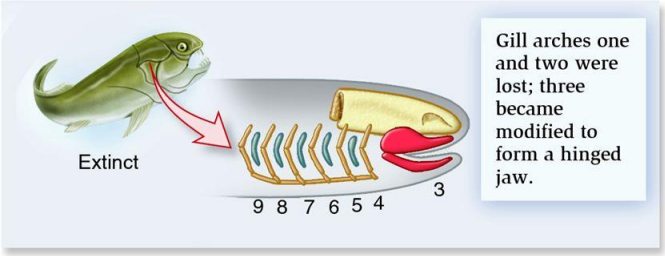

(b) Early jawed fishes (placoderms)

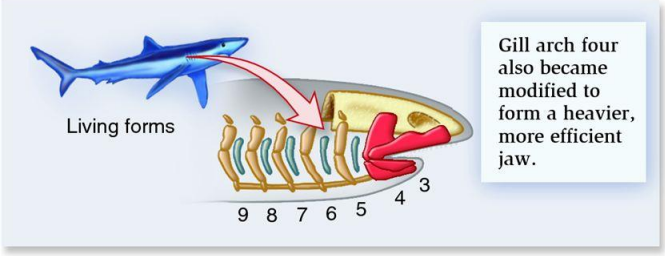

(c) Modern jawed fishes (cartilaginous and bony fishes)

Recall the ancestor of vertebrates possessed pharyngeal arches. During the evolution of vertebrates, the gill arches become modified into various structures. This represents a theme in evolution that natural selection often modifies structures already present, as if it is endlessly “tinkering” with forms over time. In this image, you can see how the gill arches have been modified into jaws in sharks.

Agnathans – vertebrates that lack jaws

I. Petromyzontoidea – Lamprey

Lampreys are classified as vertebrates, they have very small cartilaginous vertebral elements located near the notochord. Lampreys lack ribs, paired fins and girdles. They have a have a circular mouth with teeth-like structures that are keratinized. They are not mineralized teeth similar to gnathostomes, which are made of the hard mineral hydroxyapatite.

When viewing a lamprey:

- Count the number of external gill slits
- Identify the notochord

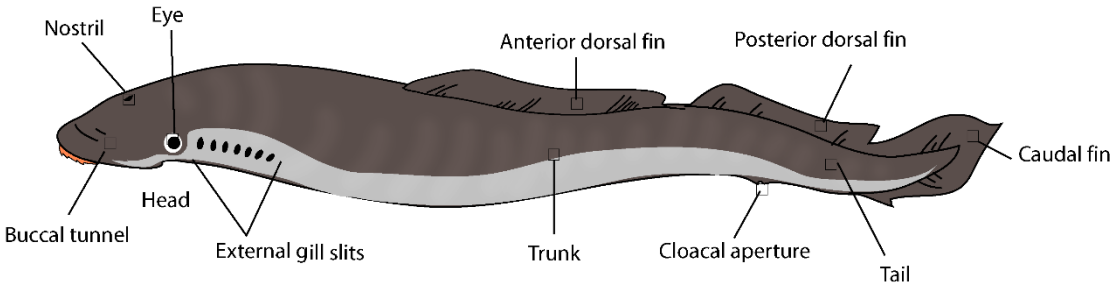

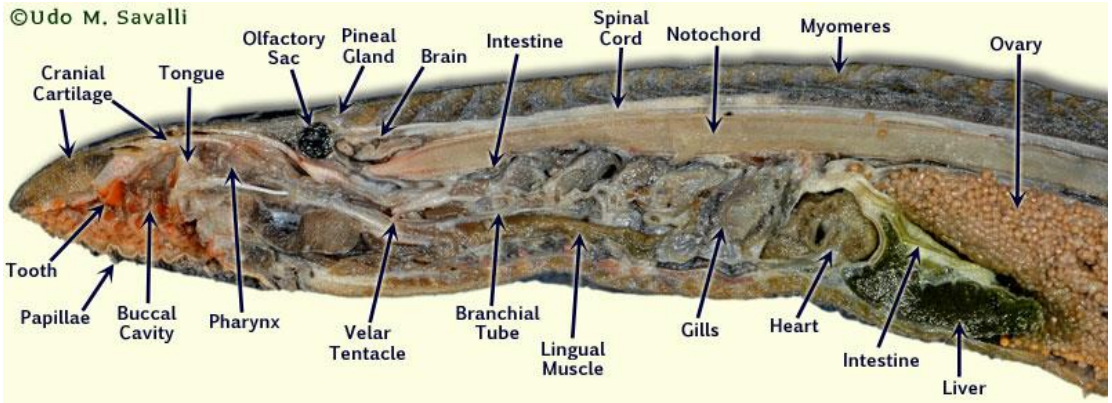

The midsagittal section of an adult lamprey. Sagittal sections are the right and left halves of a bilateral organism.

Gnathostomes – Jawed vertebrates.

This group includes 99% of all living vertebrates, or about 60,000 species. They have jaws, paired appendages, mineralized tissues including teeth and cartilage. The jaw is actually derived from the first gill arch of agnathans.

II. Chondrichthyes – Cartilaginous fish/sharks.

Modern sharks and rays have a cartilaginous skeleton lacking well developed ribs. If they are taken out of the water, their own body weight can crush their organs. The advantage of a cartilaginous skeleton allows for added maneuverability and flexibility compared to a skeleton made of hard, mineralized bone. The upper jaws of sharks are not connected to the cranium, allowing them to move forward to help in feeding

Shark Skull:

A. **Mandibular Arch** – formed by the upper and lower jaws
B. **Hyoid Arch** – includes the tongue bone and the hyomandibula, a bone used to suspend the upper jaw of sharks.
C. Branchial Arch – Form the 5-7 gill arches found in sharks

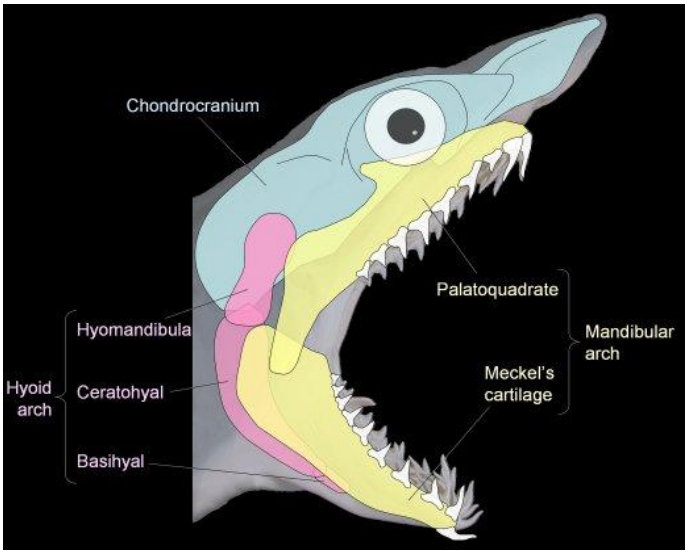

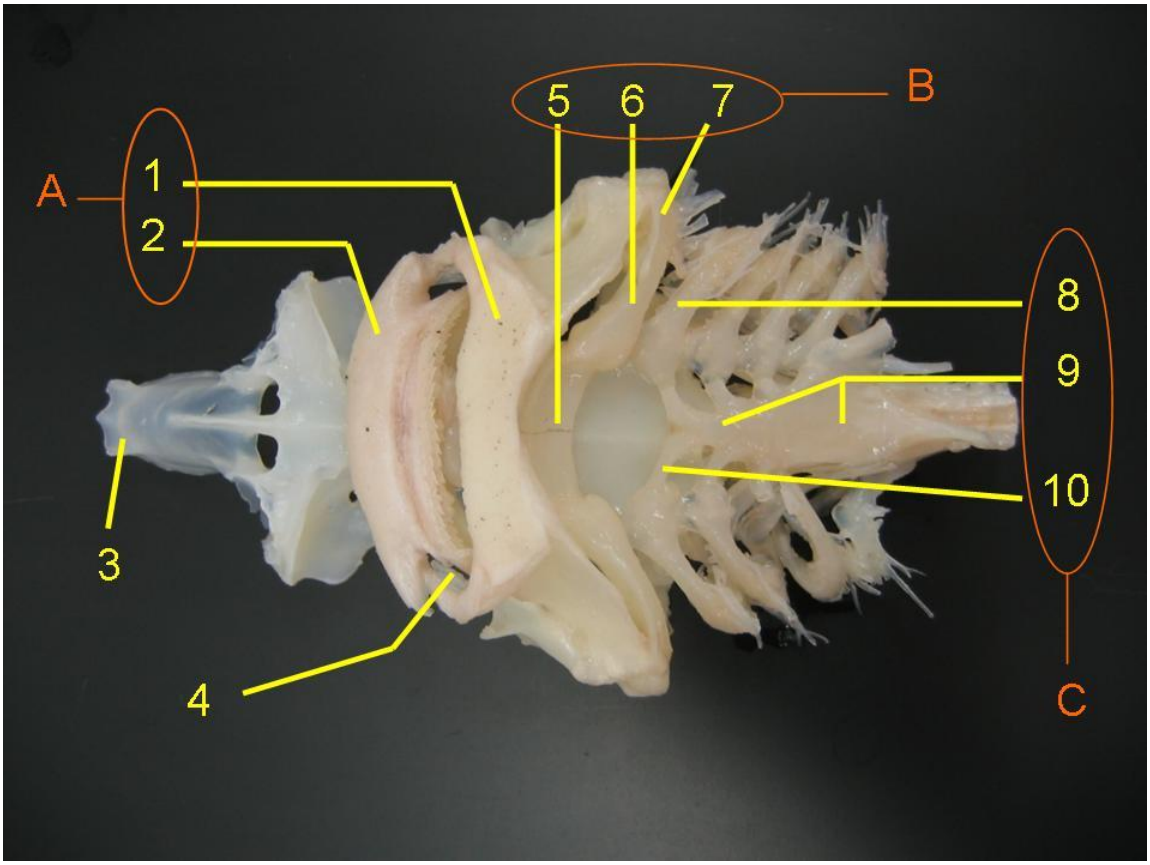

These skull structures get the name “arch” because they are derived from the pharyngeal arches used for filter feeding in cephalochordate and urochordates and the gills of agnathans. That’s why pharyngeal arches are also called gill arches. Gill arches have evolved into various structures in different vertebrate lineages. A common theme in evolutionary adaptation, is that evolution by natural selection is similar to “tinkering” with structures already present. As you learn about other vertebrate lineages, you will see how the gill arches are adapted to perform different functions. In the sharks, the first gill arch (**mandibular arch**) has been modified into the upper and lower jaws that bear the teeth. The **hyoid arch** has been modified into a tongue and the hyomandibula, which is used to help suspend the upper jaw of sharks. The **branchial arch** forms the gill arches in sharks used for gas exchange.

Teeth

Identify the teeth in the shark, they are mineralized with hydroxyapatite. Each tooth is basically the same shape throughout the mouth. Sharks usually have rows of teeth and are constantly replacing their teeth. As a result, shark teeth are abundant in the fossil record and are often the only fossils that remain of some species of sharks. The tooth shape can reveal not only the size and species of shark, but can provide insight into their feeding ecology.

Vertebral column

Locate the spine, note how the ribs are basically absent. The vertebrae are made of cartilage and doesn't fossilize well.

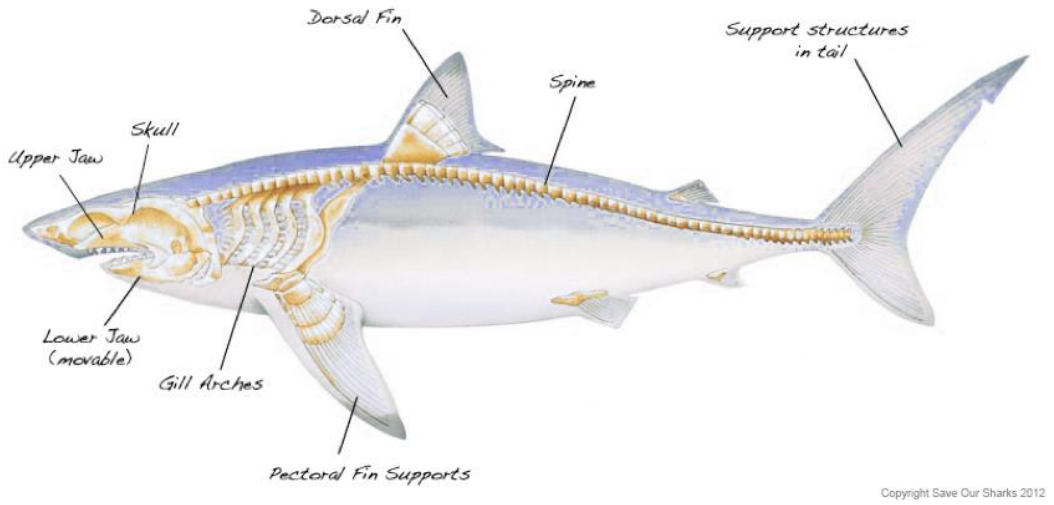

Pelvic and pectoral girdles

The pelvic girdle is very small consisting of a single piece of cartilage attaching the small pelvic fin. There are differences between the male and the female, where the male has a modified pelvic fin for clasping onto the female for internal reproduction, a derived character in sharks. The pectoral girdle is larger to support the larger pectoral fin, the fins are supported by dermal rays.

III. Osteichthyes – Bony Fish

Bony fish have a skeleton composed primarily of mineralized bone made by osteocytes rather than cartilage. Bone and cartilage are both forms of connective tissue with embedded cells. Cartilage typically lacks vascular tissue and is thin and flexible. Bones are highly vascularized and the matrix where the cells are embedded are calcified, making them very strong.

The bony fish, (or more correctly, the bony vertebrates) are divided into two major groups, the ray-finned fish (Actinopterygii) and the lobe-finned fish (Sarcopterygii). There are approximately 30,000 species of ray-finned fishes. While there are only about 9 extant species of lobe-finned fishes, their ancestors gave rise to the tetrapods nearly 375 million years ago.

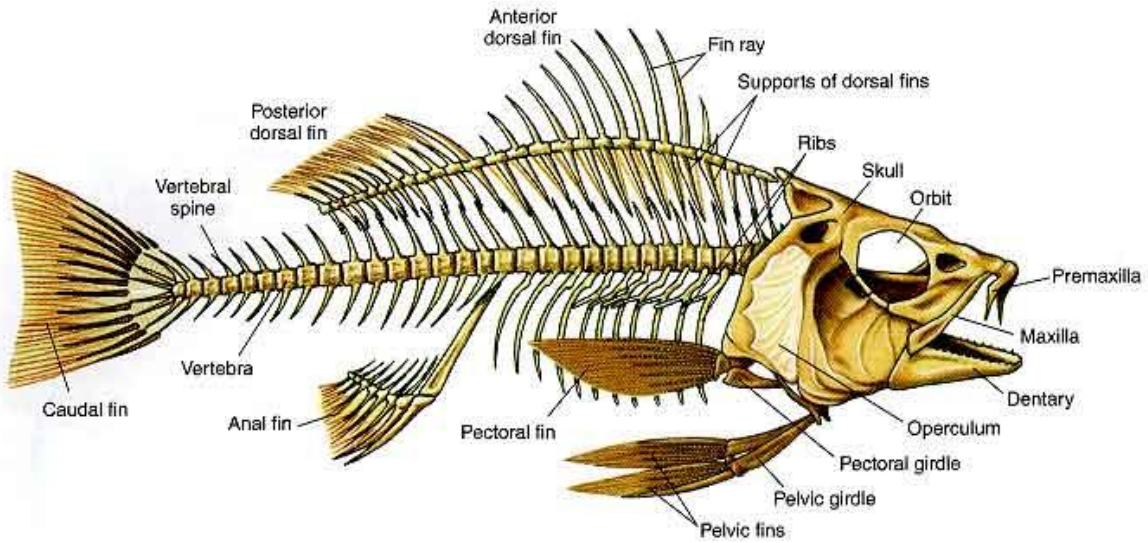

Skull

There are many bones in the skull. The upper jaw includes the **premaxilla** and the **maxilla**. Both are teeth bearing structures. The lower jaw is formed by the **dentary**, which also bears teeth. The **operculum** is a bony flap that covers the gills to protect them.

Teeth

Similar to sharks, ray-finned fish are homodonts with mouth filled with similar teeth that are replaced throughout their life. In several groups of fish, including the blennies, they the teeth are modified to deliver a venomous bite, similar to snakes.

Vertebral column

Boney fish have better developed ribs than cartilaginous fish. The notochord is further reduced, but still runs through the middle of the vertebral column. The vertebral column ends at the caudal fin. Notice that the bones that support dorsal fins are not directly attached to the vertebral column.

Pelvic and pectoral girdles

Bony fish have a pectoral girdle that attaches to the pectoral fin and to the skull near the operculum. The pelvic fin is attached to the pelvic girdle, which is similar to the pectoral girdle and fin. The position of the girdles and fins varies wildly in different fish groups. In the perch and many other teleost fish, the girdles and fins are located on the anterior end of the fish near the head. In salmonids (Example: Atlantic Salmon), the pectoral fin and girdle are located more ventrally, and the pelvic fin and girdle are located ventrally near the middle of the fish.

Questions

1. Where is the pelvic girdle attached to the body?

2. Describe the derived features of the bony fish compared to a shark.

3. What features do the bony fish share in common with a shark?

Tetrapods

The first tetrapods evolved from a lobed-fin fish in the Devonian Period about 375 million years ago. Moving onto land presented these early organisms with new challenges. Not only did they have to evolve to breathe the air and prevent desiccation, but their skeleton had to evolve to support their body weight and allow them to move around on land. In the tetrapods, the pelvic and pectoral girdles became increasingly modified to hold up more weight. The limbs typically follow a one bone, two bone, and lots of bone pattern that is conserved in most tetrapods. The notochord is further reduced to forming disk between the vertebrae offering support and mobility and the vertebrae themselves also become increasingly differentiated to accommodate different lifestyles. Cervical vertebrate evolved very early in the tetrapod lineage, they allowed the animal to move its head independently of the body. You notice this every time you shake your head "no", approximately 70% of the head movement is possible due to the unique shape of the first two cervical vertebrae.

IV. Amphibians – Anura and Caudata

Caudata (salamanders) – In some ways, modern salamanders resemble the first terrestrial vertebrates dating back to 375-365 million years ago. Both larvae and adults maintain a tail throughout their life. They have four limbs, with the general bone structure of one bone, two bones, and lots of small bones. Some species retain their gills into adulthood so that they never have to leave their aquatic environments. Salamanders possess the unique ability to regenerate lost limbs. They never have more than four toes on their front limbs, and five on their hind limbs. Some species of salamanders have fewer toes and others have lost their hind limbs.

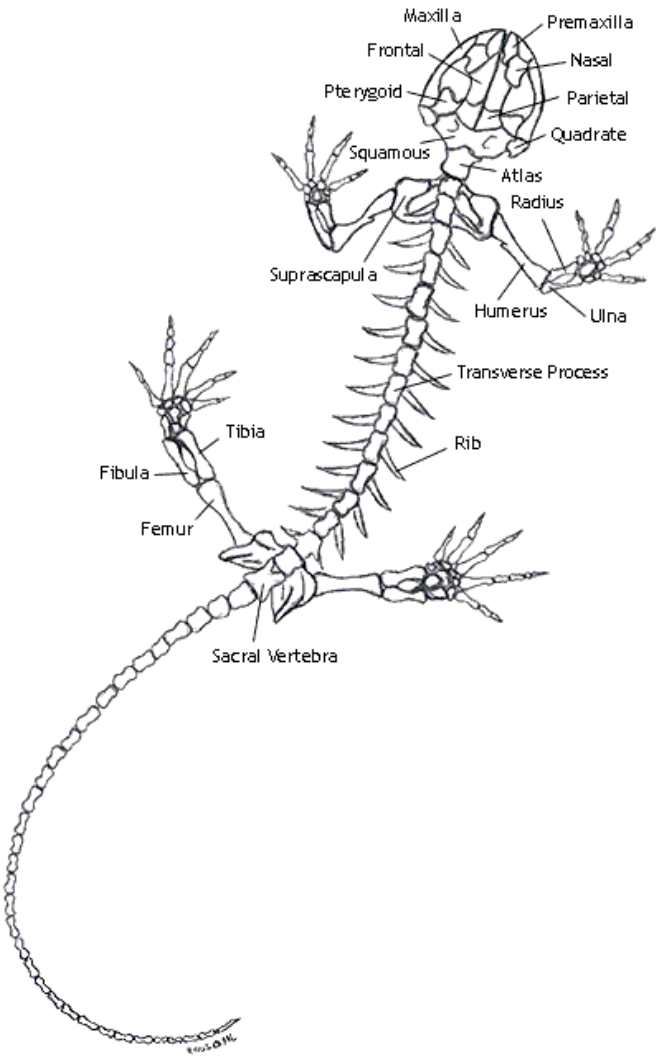

Salamander skull

The skull has a premaxillary and maxillary region that bear teeth.

Teeth

Salamander larvae have small conical teeth. The adults sometimes show specialization in their teeth, a derived feature.

Vertebral column

There are four regions present in the vertebral column. The **cervical** region consist of just one bone joining the skull to the rest of the vertebral column. The longest part is the **thoracic** (trunk region) with very small wishbone like ribs. The **sacral** region has just one vertebra whose ribs join with the pelvic girdle and hind limbs. The caudal regions extends beyond the pelvic girdle.

Pectoral girdle

Only the scapula is ossified, whereas the coracoid is cartilage. Similar to the other tetrapods and the hind limbs, the fore limbs have a single humerus connected to the radius and the ulna. The front are composed of smaller bones including the carpels, metacarpals, and phalanges.

Pelvic girdle and hind limbs

The pelvic girdle is largely cartilaginous, connecting with the hind limbs. Keeping with the one bone, two bones, and lots of bones pattern in tetrapods; the hind limbs possess a femur, which is attached to the tibia and fibula. The hind foot is comprised of smaller bones including the tarsals, metatarsals, and phalanges.

Anuran (Frogs) – Frogs are tailless amphibians whose origins date back to at least the Triassic 200 million years ago, but molecular evidence indicates an early origin dating back to the Permian 265 million years ago. Larval frogs have tails, which are lost as they mature into adults. They only have about 10 vertebrae with very poorly developed ribs. They also have large jaws allowing them to acquire larger prey.

Frogs skeletons have become well adapted to jumping. In the hind limbs, the tibia and fibula are fused to increase their strength, allowing them to be better jumpers. The metatarsals are elongated for a longer take-off time, further increasing their jumping distance. The tail vertebrae are fused into an urostyle inside the pelvis, enabling the force of the legs to be better transferred to the body when they jump. In the forelimbs, the radius and ulna are also fused, strengthening the forelimb to absorb the impact of their jump

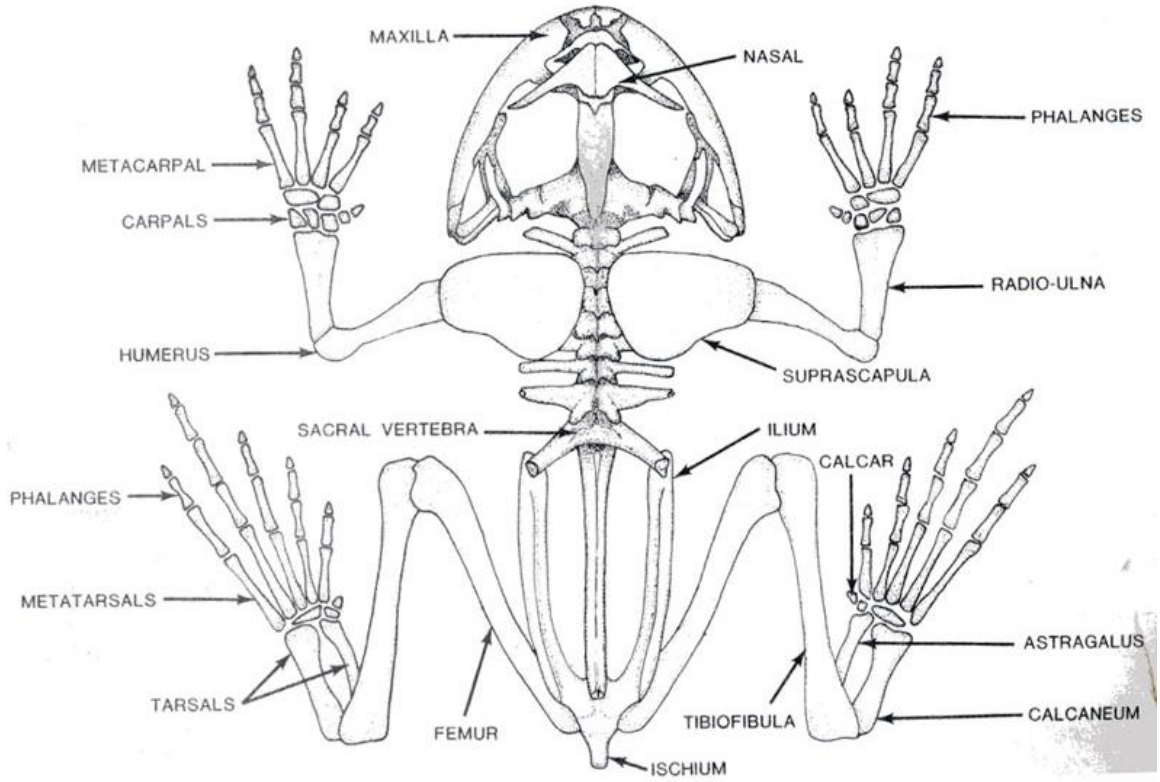

On the frog skeleton, make sure you can identify the following bones.

- Sacral and caudal vertebrae
- Pectoral girdle
- Forelimb
    - Humerus, radio-ulna
    - carpals, metacarpals, phalanges
- Pelvic girdle - Urostyle
- Hind limb
    - Femur, tibia, fibula
    - Phalanges

Skull architecture of amniotes

Amniotes first evolved more than 300 million years ago. This group is defined by presence of the amniotic sac, a fluid filled bag that keeps the growing embryo in water. Amniotes also have internal fertilization, another key adaptation reducing their dependence on returning to water for reproduction. Ancestral amniotes had scales to prevent desiccation. Early in amniote evolution, the group split into two major lineages, the Sauropsida and the Synapsida. Suaropsida includes all modern reptiles and birds, and several extinct lineages. Modern reptiles and birds belong to a sub-group called the Diapsida. Meaning that modern amniotes currently belong to two major groups, the synapsids (mammals) and the diapsids (reptiles and birds). The evolution of these groups can be traced through changes in the skull morphology. Diapsida means “two arches” and synapsida means “one arch”. These arches are features of the skull and should not be confused with the gill arches that have been modified into various features. Although, turtles have lost their arches and are considered anapsids. It is unclear if the anapsid condition in turtles is derived or plesiomorphic

There are many bones associated with the skull, we will focus on just a handful. The temporal fenestrae are anatomical features of the skulls of several types of amniotes, characterized by bilaterally symmetrical holes (fenestrae) in the temporal bone. Depending on the lineage of a given animal, two, one, or no pairs of temporal fenestrae may be present, above or below the postorbital **(po)** and squamosal **(sq)** bones. The fenestrae possibly evolved with higher metabolic rates and an increase in jaw muscles. Bigger jaws would allow them to process more food. In modern mammals, the temporal fenestrae are greatly reduced or merged with the eye orbit. The ancestral amniotes lacked fenestra, so the synapsid and diapsid traits evolved independently. It’s the changes in the skull morphology that allowed amniotes to radiate into many different lineages, exploiting very different resources.

Ribs are attached to the thoracic vertebra.

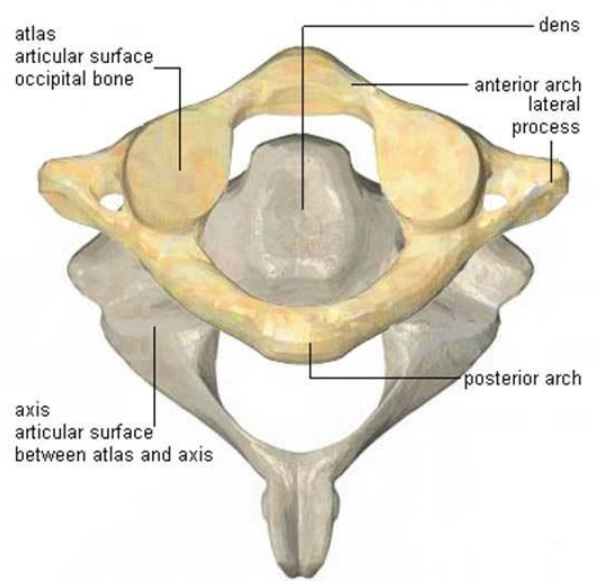

The **cervical vertebrae** in the amniotes are specialized to allow more movement of the head. The first two vertebrae are called the **atlas** and the **axis** where the atlas attaches to the cranium in amniotes

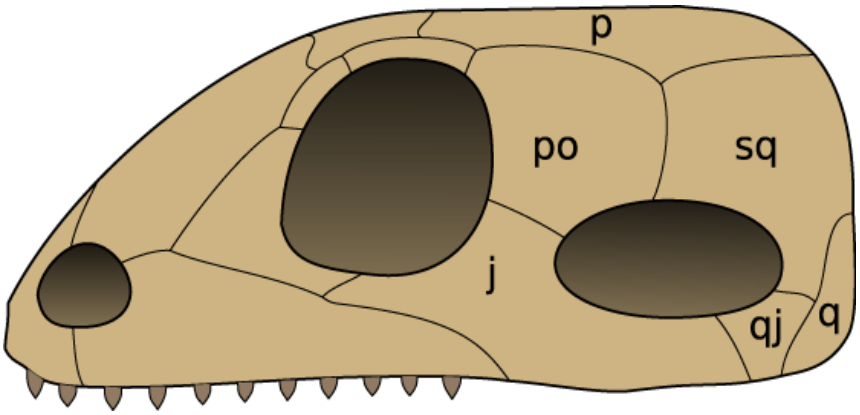

Synapsids possess one temporal fenestrae located behind the eye orbital. However, the opening is greatly reduced in modern mammals.. These early synapsids are usually called pelycosaurs, which included Dimetrodon, a stem or proto-mammal.

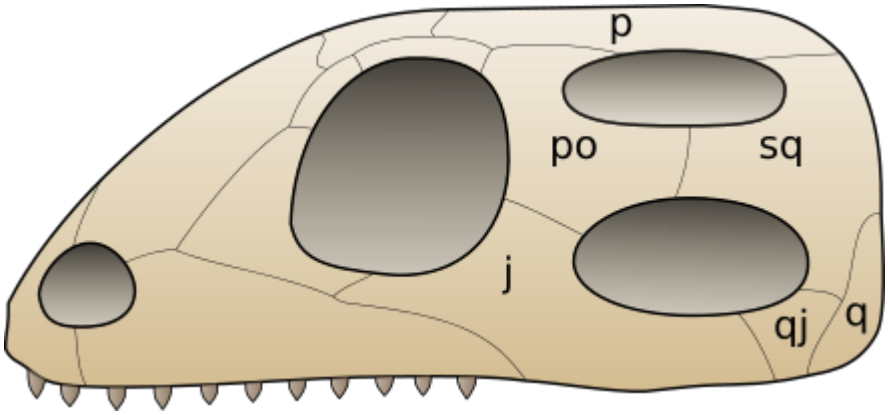

Diapsids possess two temporal fenestrae located behind the eye orbital. The two temporal fenestra allowed for stronger jaw muscles and the ability to open the jaws wider.

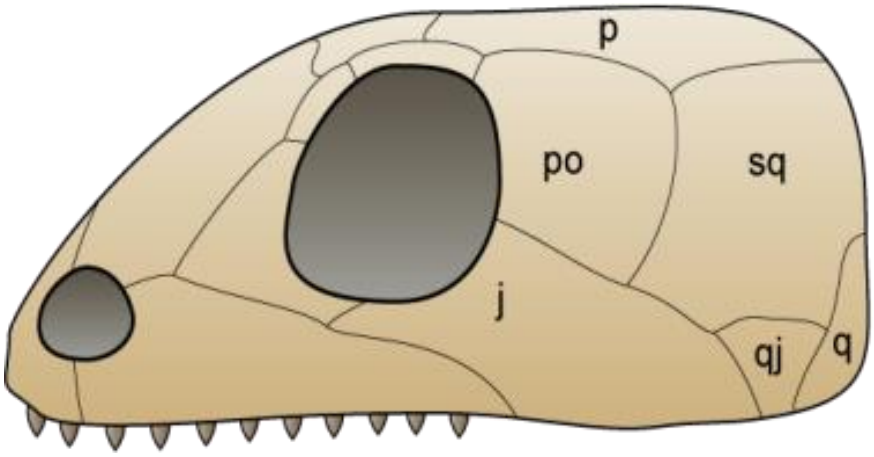

Anapsids do not have openings in the skull. The ancestral amniotes lacked temporal fenestra. However, it is unclear whether this condition in turtles is ancestral or derived.

V. Testudinata – turtles

Turtles are clearly a reptile, they are ectothermic and have scales. However, their relation to other reptiles including the Lepidosaurs and Archosaurs is less clear. The confusion arises because turtle skulls lack temporal fenestra, they are anapsids. The ancestral condition of amniotes actually lack the fenestra and were anapsids. However, it is unclear whether or not the condition in turtles is derived or ancestral. The latest large scale phylogenies based on molecular data indicate that they are a derived diapsid and sister group to the archosaurs.

Turtles are instantly recognizable by their shell that completely encloses all the vital organs. It is made of dermal bone and is covered in scutes made of keratin. Elements of the skeleton, including the ribs, parts of the pelvis are fused to the underside of the carapace.

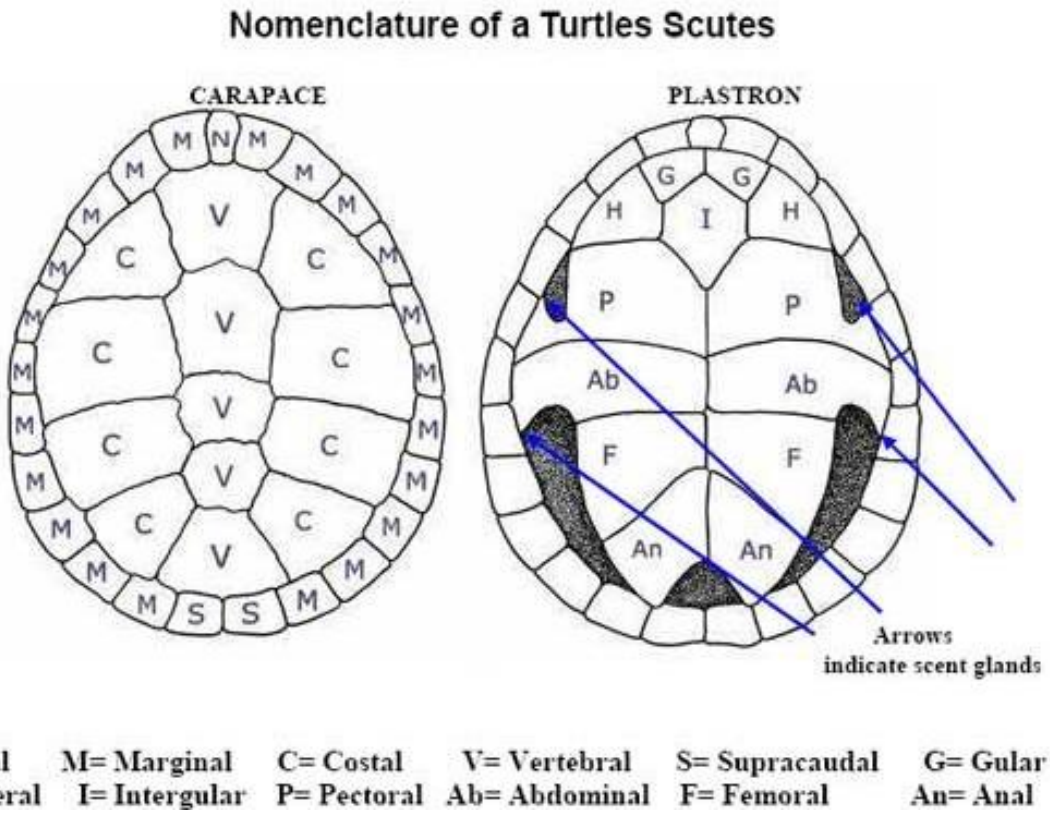

Turtle skull

Turtles have the anapsid condition of lacking temporal fenestra. They have a premaxilla and a maxilla forming the upper jaw and dentary forming the lower jaw. Neither of these structures bear teeth.

Teeth

Similar to birds, modern turtles lack teeth. They have a beak that covers the maxilla, premaxilla and the dentary.

Vertebral column

Turtles possess a cervical, thoracic, sacral, and caudal regions of the vertebral column. However, the thoracic, sacral, and the first caudal vertebra are fused with the dermal bone that forms the carapace. The sacrum is made of two vertebra, which is fused to the first caudal vertebra.

Girdles and limbs

The pelvic girdle consists of three parts, the ilium, pubis, and ischium. The hind limb has a femur, tibia, and fibia, along with multiple smaller bones, similar to other tetrapods. Turtles lack a sternum, but they have a plastron instead. The pelvic girdle lies in the rib cage, which is unusual compared to other vertebrates. The forelimb is also similar to other tetrapods with a humerus, radius, and ulna, with smaller bones forming the front feet.

Carapace is the dorsal side of the turtle and the plastron is the ventral side.

- Examine the skull and look for the anapsid condition.
- Notice how the ribs are fused to the carapace.
- The forelimb includes the humerus, radius, ulna and carpals.
- Locate the pectoral and pelvic girdle.
- The hind limb includes the femur, tibia, fibula, and carpals

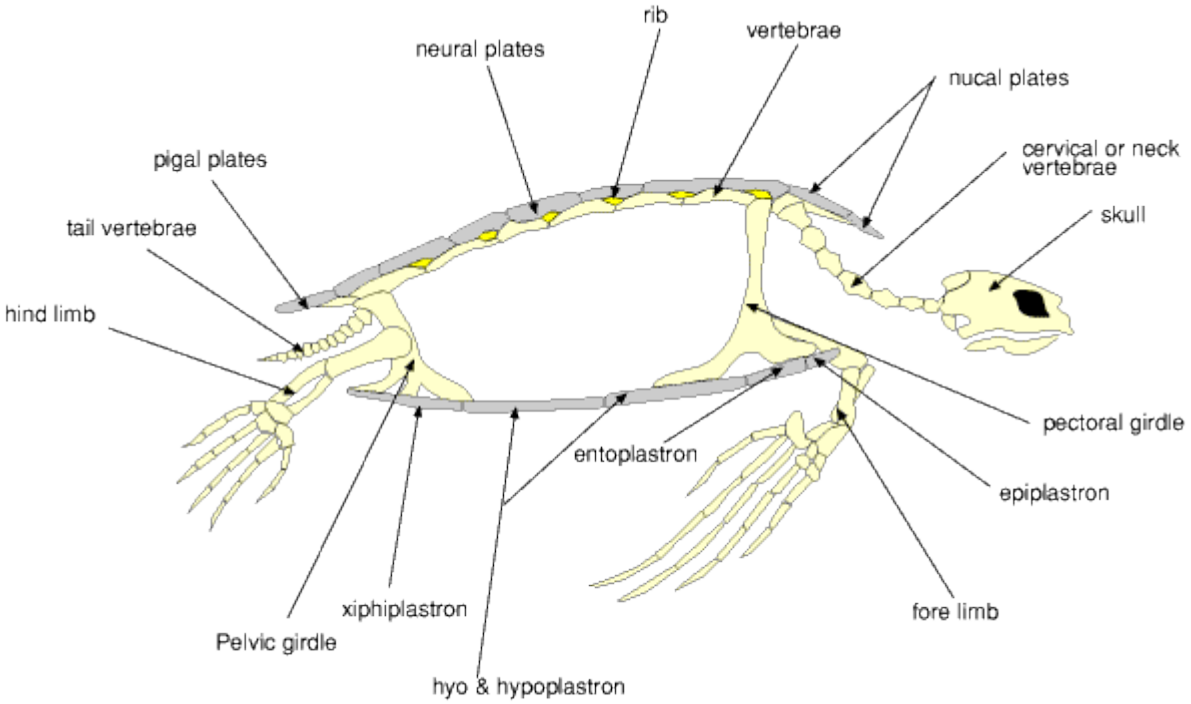

Lateral or side view of a generlised sea turtle skeleton

VI. Lepidosauria – Squamates (snakes and lizards)

. When viewing an articulated lizard skeleton, notice how the legs are to their side giving them a sprawling appearance. The forelimbs and hind limbs follow the basic one bone, two bones, and many bones pattern.

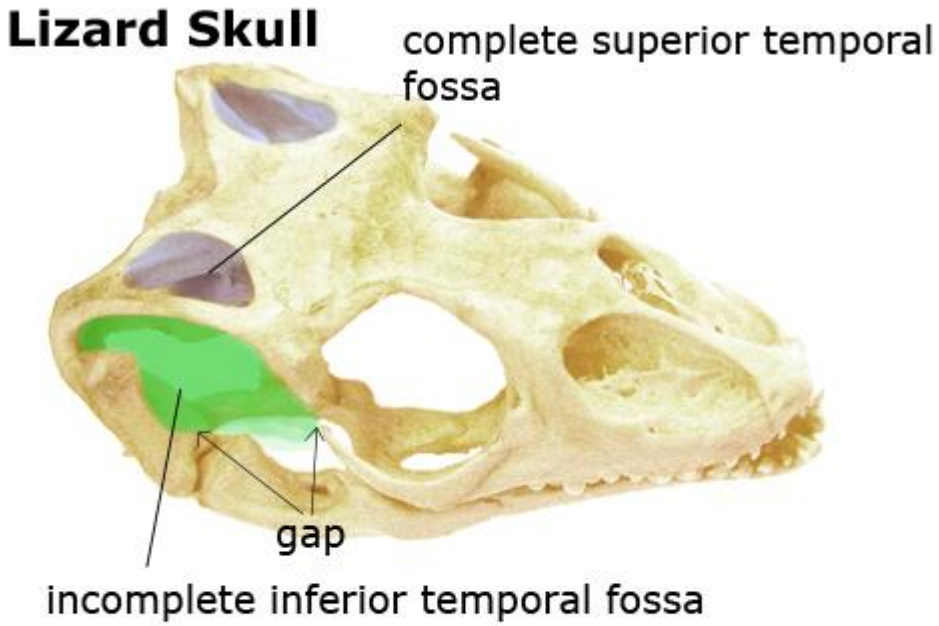

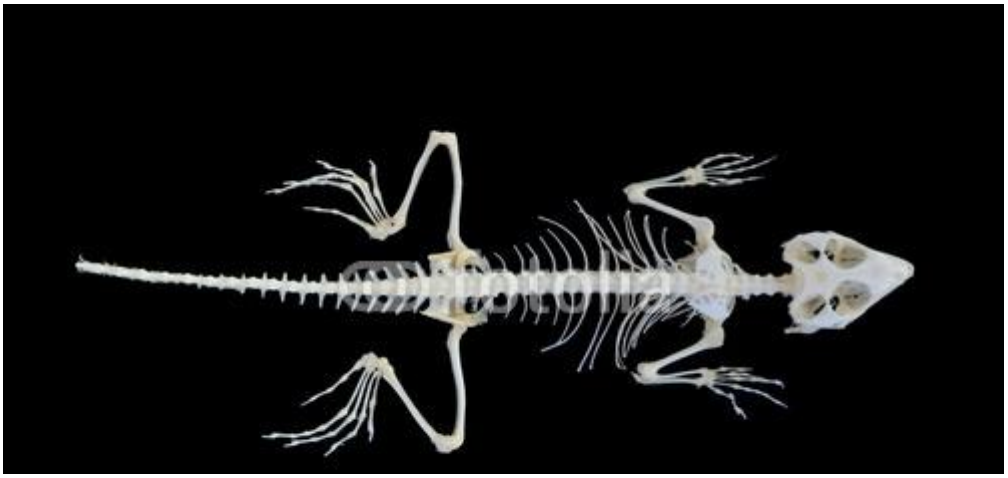

An articulated skeleton of a lizard. The legs are to the side giving it a sprawling appearance.

Lizard Skull

On the lizard skull look for the two fenestral openings behind the eye, which is the diapsid condition. The lower jaw is made of several bones and the dentary bears the teeth

Teeth

Lizards are homodonts and are able to replace their teeth throughout their life.

Vertebral Column

Lepidosaurs possess cervical vertebra, rib bearing, thoracic vertebrae, sacral vertebrae, and caudal vertebrae.

Girdles and limbs

VII. Archosaurs – Crocodilia (alligators and crocodiles)

Archosaurs are the second major extant group of sauropsids, with the other being the Lepidosaurs. Saurpsida includes all modern reptiles and numerous extinct forms. Archosaurs and Lepidosaurs are also nested within Diapsida. The two temporal fenestra of diapsids are easily observed on the alligator skull.

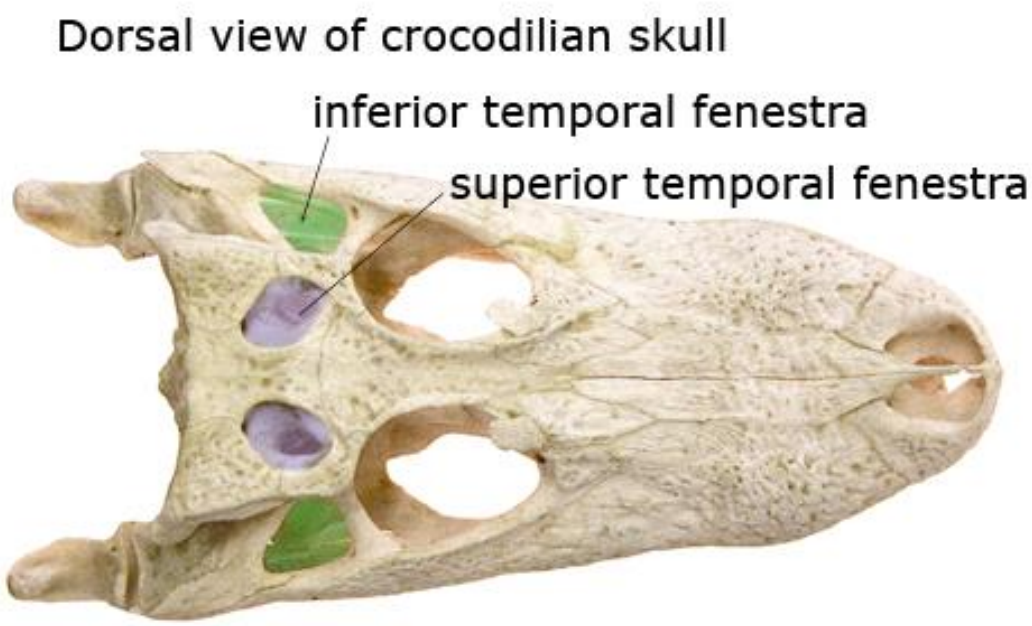

Alligator skull

The most obvious feature of the alligator skull is its long flattened snout. Notice that it's not formed from the addition of extra bones, but rather by modifying the shape of bones already present. The modification of structures already present is a common evolutionary theme. Alligators are diapsid, you should locate the two fenestra in the skull.

Teeth

Alligators are homodonts, with a mouthful of similarly shaped teeth. Alligators can replace their teeth when they are lost. Similar to other homodonts, alligator teeth are well adapted to grasping prey, but are not well suited for chewing. The teeth are attached to sockets in the alligator's jaws.

Vertebral column

The vertebral column of crocodiles is divided into five regions: **cervical**, **thoracic**, **lumbar, sacral**, and **caudal**. Similar to Lepidosaurs, the first two cervical vertebrae are modified into the atlas and the axis, allowing for greater head movement. Ribs are attached to the **thoracic** vertebrae and are used to protect the organs of the thorax including the heart and lungs. There are 5 **lumbar vertebrae**, primarily used for mobility. Two **sacral** vertebrae attach to the pelvic girdle forming the sacral region. The caudal vertebrae extend beyond sacral region.

Girdles and limbs

The pelvic girdle in crocodilians consists of three parts, the ilium, ischium and pubis. The ilium joins with the two sacral vertebrae. The hind limbs are composed of a femur, fibula, and tibia connected to metatarsals and phalanges. The pectoral girdle consists of a scapula and the coracoid which is attached to the humerus. The humerus is attached to the radius and ulna, which in turn are connected to the smaller bones forming the front feet.

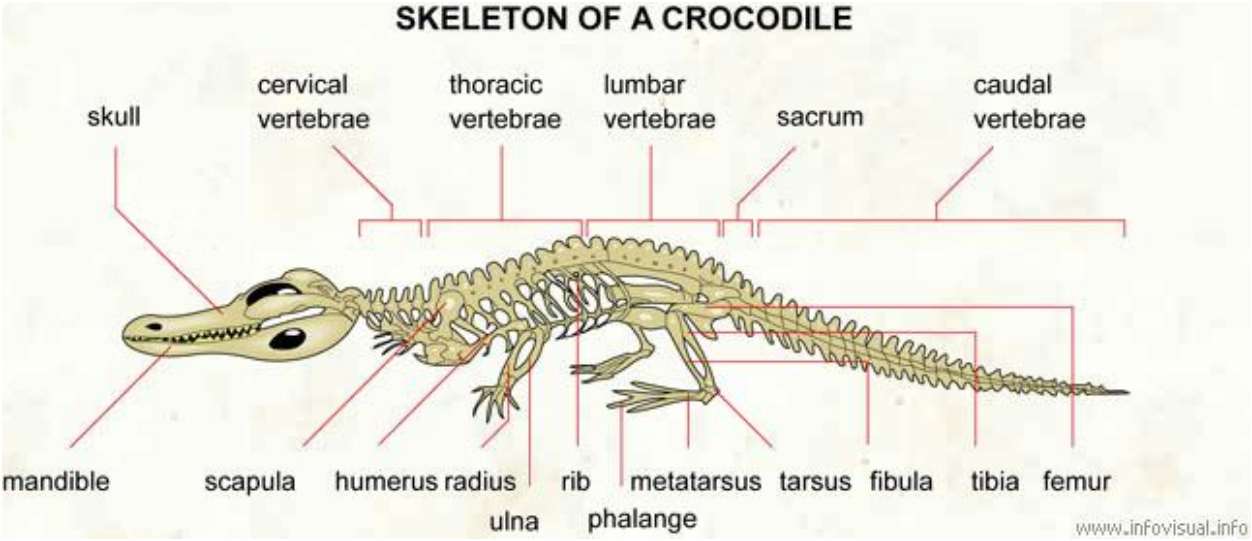

VIII. Archosaurs – Aves (Birds)

The avian skeleton is well adapted to flight. Major bones, especially the skull and the bones of the pelvis region are fused for extra strength. The major bones are also filled with air, making them slighter. And lastly, birds have lost their teeth.

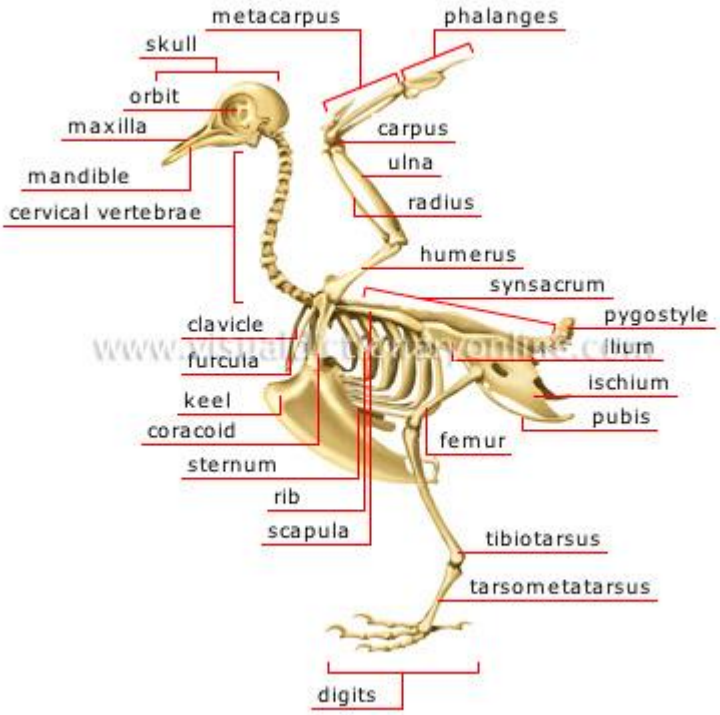

Avian Skull

The bones in bird skulls are fused. The premaxilla forms the tip of the beak in birds, followed by the maxilla. The lower jaw is formed by the dentary. Bird beaks can vary greatly is size and shape from very strong bills for cracking large seeds to very delicate beaks used by hummingbirds to drink nectar from flowers. Birds have very large eyes surrounded by specific bone called the sclerotic ring.

Teeth

Modern birds do not have teeth, similar to turtles.

Vertebral column

The avian vertebral column is highly modified for flight. The most obvious difference from other tetrapods is the high degree of fusion, especially in the last thoracic vertebrae, the lumbar, sacral, and first caudal vertebrae, which forms a feature called the **synsacrum**. The synsacrum is also fused with the pelvic girdle, specifically the ilium. The cervical vertebrae remain unfused to allow movement of the head. By fusing the vertebrae, especially to the pelvis, improves the strength of these structures while not adding weight.

Girdles and limbs

As stated above, the pelvic girdle has fused with multiple vertebrate forming a single structure called the **synsacrum.** The ilium, ischium, and pubis are all fused together. The hind limbs are also modified, they have a femur, but the fibula has been greatly reduced in size. The tibiotarsus connects to the femur and is the result of the fusion portions of the tibia and some of the tarsal bones. Many of the smaller bones in the foot (tarsals and metatarsals) have fused to form the tarsometatarsus. The toes are made of the phalanges.

The pectoral girdle and forelimbs are highly modified for flight. There are three bones in the pectoral girdle, the scapula, the coracoid, and furcular (also known as the wishbone). The furcular is formed from the fusion of the two clavicles. The sternum has a large keel for the attachment of flight muscles. Flight feathers are attached to the forelimbs. The outermost feathers, called primaries, are attached to the smaller bones of the tetrapods limbs, and the secondaries attach to the ulna.

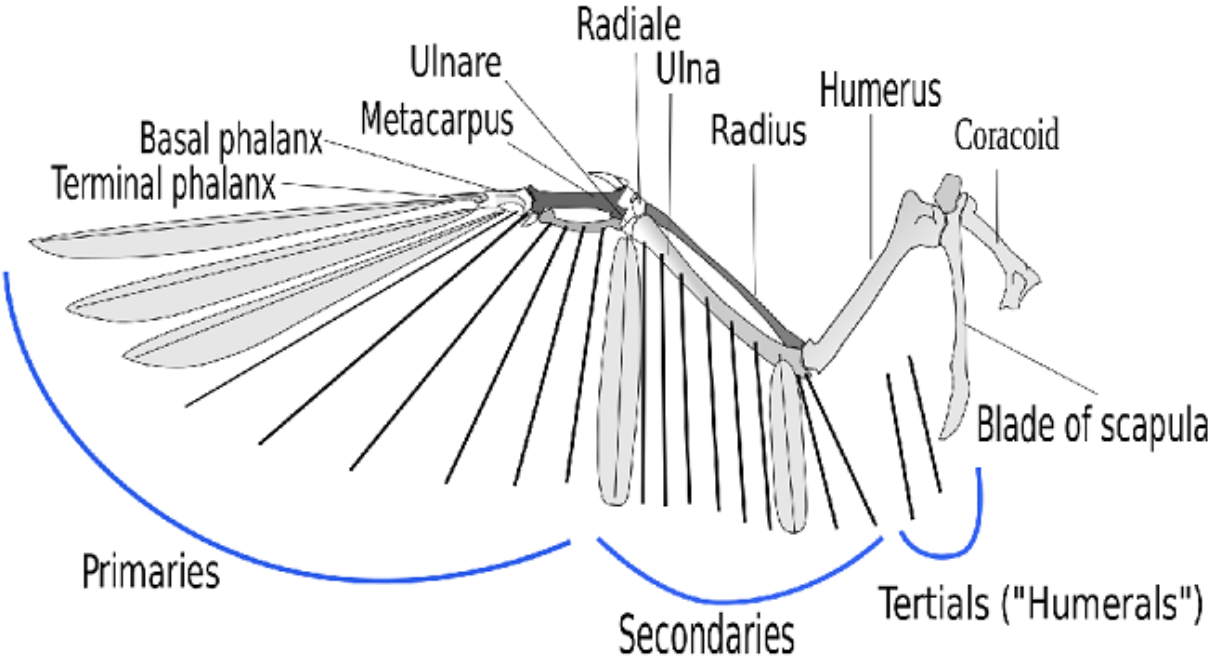

IX. Mammalia – Mammals

Mammals are synapsids, one of the two living amniote lineages, the other being the Sauropsida, with all living reptiles including the birds nested in the diapsids. Mammals have numerous adaptation that have allowed them to be incredibly successful.

Mammal skull

Mammal skulls are highly derived, and the temporal fenestra has been greatly reduced. The bones are highly fused, especially in the cranial region to protect the brain. Teeth arise from the premaxilla and the maxilla. The dentaries form the jaw and also have teeth.

Teeth

Mammals are heterodonts, meaning they have different specialized teeth in their mouth called their dentation. Dentation is so important in mammals that it can be used to identify modern mammals and fossils. There are four types of teeth, incisors in the front, canines next to them, premolars along the side, and molars in the back. These teeth are highly modified depending on the type of mammal and what they eat. Mammalian teeth are able to come together when the mouth is shut, allowing mammals the ability to chew their food, beginning digestion while in the mouth.

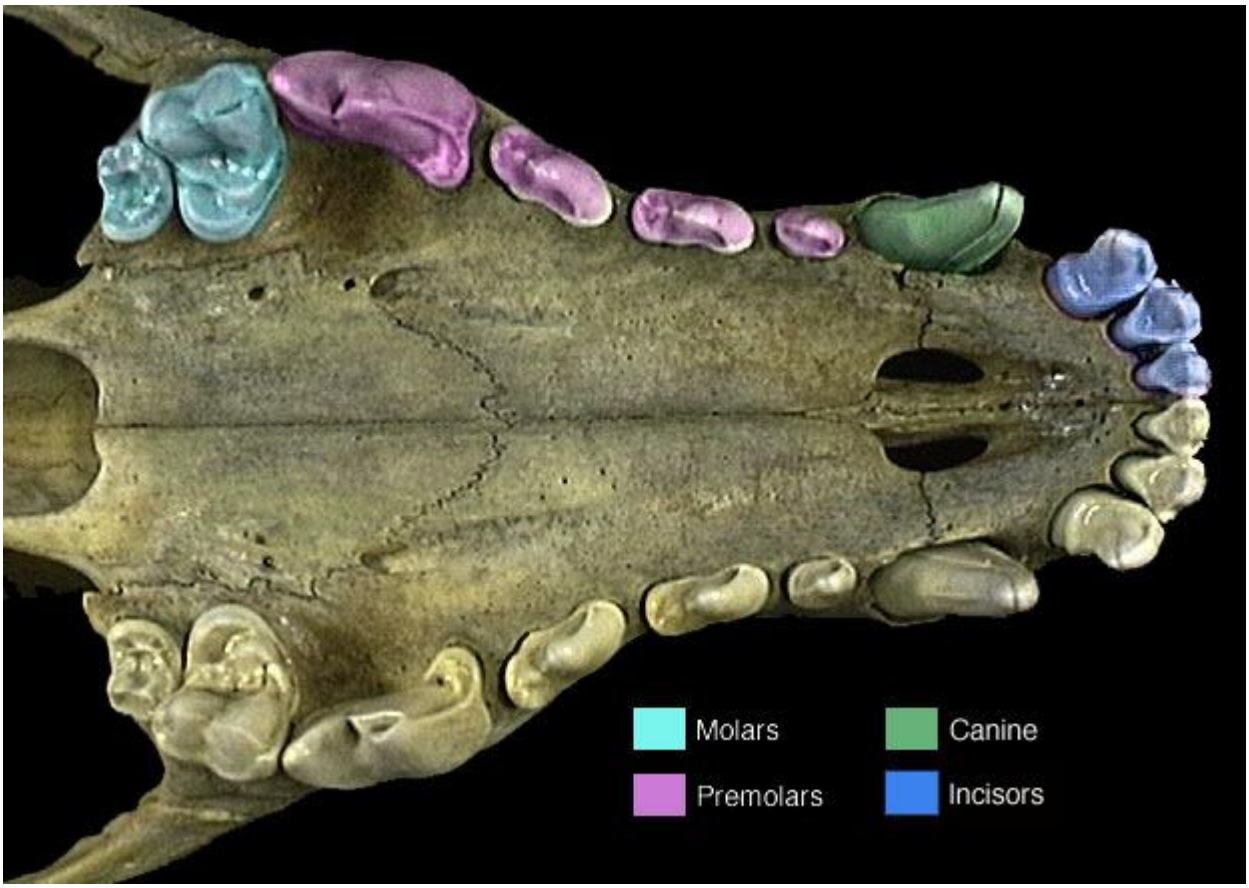

Mammals also have only two sets of teeth, the milk teeth (baby) and the adult teeth. When adult teeth are lost, mammals are not able to replace them.

Vertebral column

Mammals possess five distinct regions, including the **cervical**, **thoracic**, **lumbar**, **sacral**, and **caudal** regions. All mammals have seven cervical vertebrae, even Giraffes with their long necks. Similar to other amniotes, the first two cervical vertebrae include the **axis** and the **atlas** to allow the head to move. In humans, about 70% of the head movement comes from axis and the atlas. Ribs are attached the thoracic vertebrae, the lumbar vertebrae are used for support and mobility. The sacral vertebrae are fused to form the **sacrum**. The number of caudal vertebrae varies in each mammal group depending on the tail length. In humans, the last two bones are fused forming a **coccyx**, which is similar to the urostyle in frogs.

Pectoral girdle and forelimbs

Mammals typically have a claivicle, coracoid process, and scapula. The coracoid process and scapula help to attach the humerus. Mammals follow the one bone, two bone, and lots of bone pattern common to tetrapods.

Pelvic girdle and hind limbs

In mammals, the pelvic girdle is formed from the fusion of the ilium, ischium, and pubis. It connects to the femur, and the hind limbs follow the general one bone, two bones, lots of bones pattern.

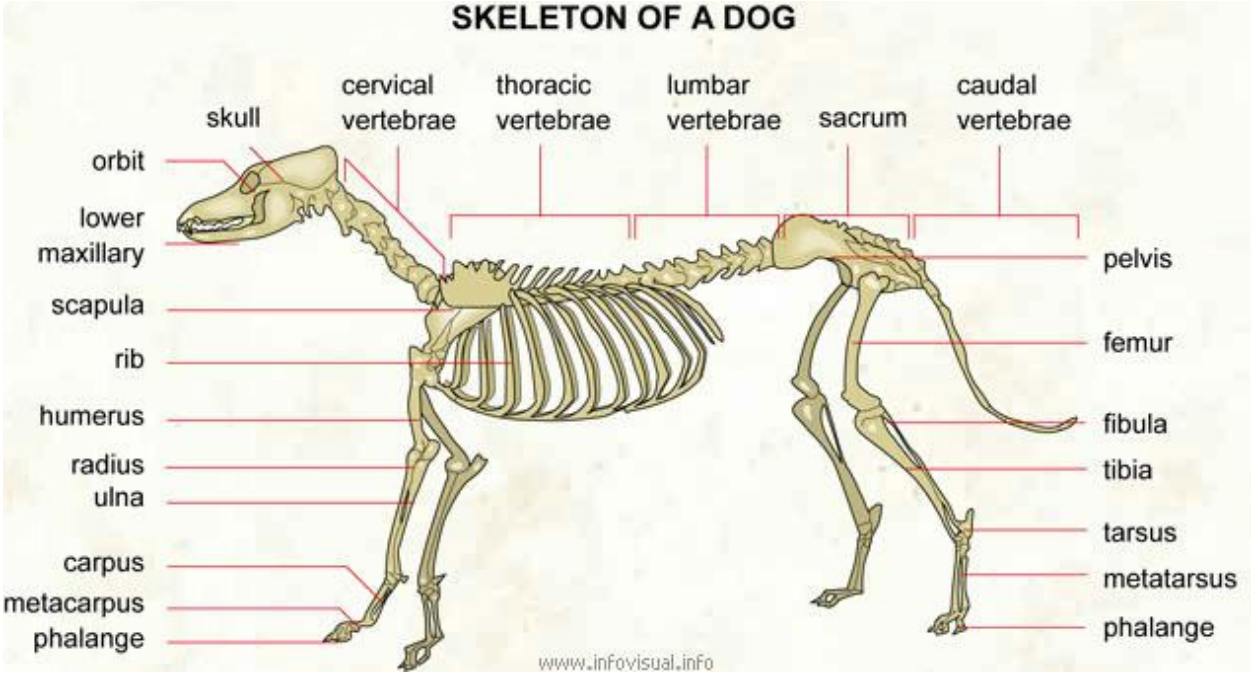

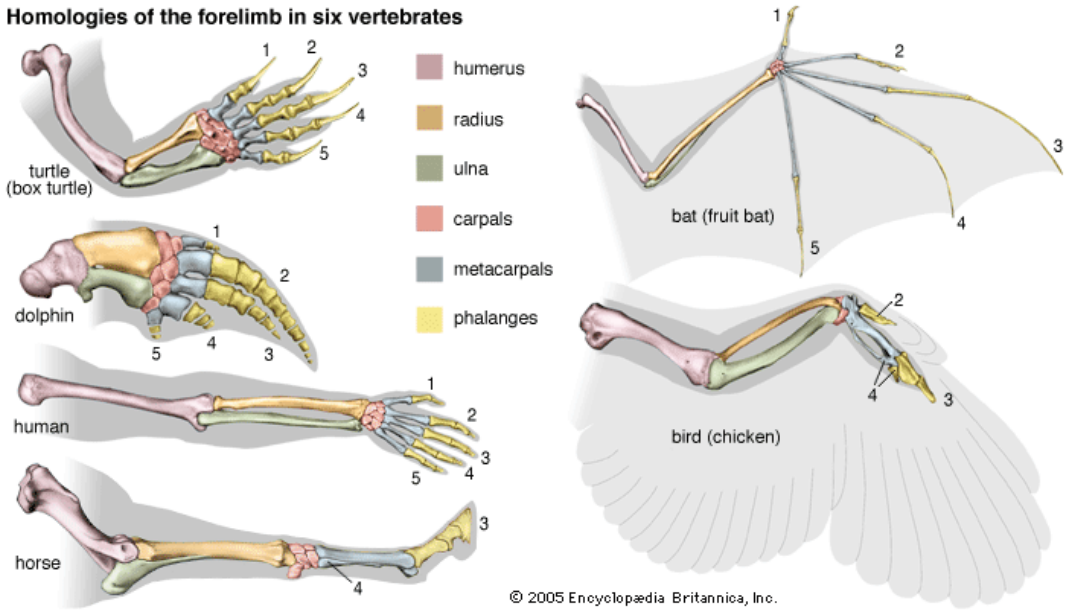
Homologies of the forelimb in six vertebrates
turtle
(box turtle)
dolphin
human
horse
bat (fruit bat)
bird (chicken)
humerus
radius
ulna
carpals
metacarpals
phalanges
© 2005 Encyclopædia Britannica, Inc.